

High prevalence of PIK3CA/AKT pathway mutations in papillary neoplasms of the breast

Megan L Troxell¹, Judith Levine^{1,2}, Carol Beadling¹, Andrea Warrick¹, Jennifer Dunlap², Ajia Presnell¹, Janice Patterson¹, Arielle Shukla^{1,2}, Neal R Olson³, Michael C Heinrich^{1,4,5} and Christopher L Corless^{1,2}

¹Knight Cancer Institute, Oregon Health & Science University, Portland, OR, USA; ²Department of Pathology, Oregon Health & Science University, Portland, OR, USA; ³Department of Pathology, Kaiser Permanente Northwest, Portland, OR, USA; ⁴Portland Veterans Affairs Medical Center, Portland, OR, USA and ⁵Division of Hematology and Medical Oncology, Department of Medicine, Oregon Health & Science University, Portland, OR, USA

Papillary lesions of the breast have an uncertain relationship to the histogenesis of breast carcinoma, and are thus diagnostically and managerially challenging. Molecular genetic studies have provided evidence that ductal carcinoma *in situ* and even atypical ductal hyperplasia are precursors of invasive carcinoma. However, papillary lesions have been seldom studied. We screened papillary breast neoplasms for activating point mutations in *PIK3CA*, *AKT1*, and *RAS* protein-family members, which are common in invasive ductal carcinomas. DNA extracts were prepared from sections of 89 papillary lesions, including 61 benign papillomas (28 without significant hyperplasia; 33 with moderate to florid hyperplasia), 11 papillomas with atypical ductal hyperplasia, 7 papillomas with carcinoma *in situ*, and 10 papillary carcinomas. Extracts were screened for *PIK3CA* and *AKT1* mutations using mass spectrometry; cases that were negative were further screened for mutations in *AKT2*, *BRAF*, *CDK*, *EGFR*, *ERBB2*, *KRAS*, *NRAS*, and *HRAS*. Mutations were confirmed by sequencing or HPLC assay. A total of 55 of 89 papillary neoplasms harbored mutations (62%), predominantly in *AKT1* (E17K, 27 cases) and *PIK3CA* (exon 20 > exon 9, 27 cases). Papillomas had more mutations in *AKT1* (54%) than in *PIK3CA* (21%), whereas papillomas with hyperplasia had more *PIK3CA* (42%) than *AKT1* (15%) mutations, as did papillomas with atypical ductal hyperplasia (*PIK3CA* 45%, *AKT1* 27%, and *NRAS* 9%). Among seven papillomas with carcinoma *in situ*, three had *AKT1* mutations. The 10 papillary carcinomas showed an overall lower frequency of mutations, including 1 with an *AKT1* mutation (in a tumor arising from a papilloma), 1 with an *NRAS* gene mutation (Q61H), and 2 with *PIK3CA* mutations (1 overlapping with the *NRAS* Q61H). These findings indicate that approximately two-thirds of papillomas are driven by mutations in the PIK3CA/AKT pathway. Some papillary carcinomas may arise from these lesions, but others may have different molecular origins.

Modern Pathology advance online publication, 6 November 2009; doi:10.1038/modpathol.2009.142

Keywords: phosphoinositol-3-kinase (PIK3CA); AKT1; breast; papilloma; papillary carcinoma

Papillary lesions of the breast are quite common, but remain enigmatic in terms of their pathogenesis and managerial implications. Papillary breast lesions are characterized by fibrovascular stalks lined by

epithelial cells, residing in cystically dilated ductal spaces. Papillomas are lined by two cell types: myoepithelial cells situated along a basement membrane and overlying epithelial cells, which may harbor any architectural or cytologic arrangement seen elsewhere in the breast, including mild to florid hyperplasia, columnar cell change, atypical ductal hyperplasia, ductal carcinoma *in situ*, or lobular neoplasia. In contrast, papillary carcinoma is conventionally defined by the lack of myoepithelial cells along fibrovascular stalks. Historical

Correspondence: Dr ML Troxell, MD, PhD, Department of Pathology, Oregon Health & Science University, 3181 SW Sam Jackson Park Rd, L471, Portland, OR 97239, USA.

E-mail: troxellm@ohsu.edu

Received 2 June 2009; revised 8 July 2009; accepted 21 July 2009; published online 6 November 2009

studies show that papillomas lacking cytologic atypia are associated with an approximately twofold risk of subsequent breast cancer, similar to that seen with usual ductal hyperplasia/proliferative fibrocystic disease.¹ However, the management of papillary lesions on needle core biopsy is difficult given the potential for epithelial variability across such lesions (sampling artifact), and there remains poor understanding of the pathogenetic implications of papillary lesions.

Relatively few studies have characterized molecular or cell-biologic aberrations in papillary lesions of the breast. Noguchi and colleagues^{2,3} showed that papillomas are clonal by studying patterns of X-inactivation, thus allowing their classification as papillary neoplasms. Several subsequent studies looking at large-scale chromosomal alterations (using methods of fluorescence *in situ* hybridization, loss of heterozygosity, and comparative genomic hybridization) have generated conflicting data regarding the presence or frequency of alterations in benign papillary lesions.^{4–9} Thus, it is unclear whether papillary neoplasms harbor genetic changes common to the pathways of breast cancer progression, and it remains undetermined whether papillary lesions represent precursors of breast carcinoma.

Recent studies have shown that point mutations in known tumor-suppressor genes and protein kinases are present in some breast cancers; however, they have been little studied in proliferative or precursor lesions. The gene encoding the phosphoinositol-3-kinase catalytic subunit (*PIK3CA*) is one of the most frequently mutated genes in breast carcinoma, with activating mutations identified in approximately one-quarter of studied cases (range 8–40%), and these mutations are present at the stage of ductal carcinoma *in situ*.^{10–20} The vast majority of mutations are located in ‘hotspots’ in exon 9 (helical domain) and exon 20 (kinase domain), with small numbers of mutations identified in other exons.^{10–20} Phosphoinositol-3-kinase is activated in response to receptor-tyrosine kinase signaling at the cell membrane, and acts through a cascade to phosphorylate AKT, itself a kinase. Activating mutations in the pleckstrin-homology domain of *AKT1* have been identified in approximately 4% of invasive breast cancers (range 1.5–8%).^{19,21–23} Activation of the *PIK3CA*/*AKT* pathway signals through mTOR to promote protein translation and cell cycling, and other effectors participate in regulation of transcription, apoptosis, cellular metabolism, etc.^{11,24–26} *PIK3CA*/*AKT* signaling is engaged in cross talk with several intracellular cascades, including RAS and estrogen receptor pathways.^{11,24–26} Given the frequency of *PIK3CA* and *AKT1* mutations in invasive and *in situ* breast carcinoma, we investigated the mutational status of papillary neoplasms as a means to study their pathogenetics, and thus their role as putative precursor lesion in breast carcinogenesis.

Materials and methods

Papillary Lesional Tissue

This study was approved by the institutional review boards at Oregon Health & Science University, and Kaiser Permanente Northwest, Portland, OR. The computerized files of Oregon Health & Science University (2000–2008) and Kaiser Permanente Northwest (2005–2008) were searched for breast specimens containing papillary lesions; core needle biopsies were excluded. All cases were reviewed by a pathologist with interest in breast pathology (MLT), and appropriate blocks from cases with adequate lesional tissue were selected. The greatest cross-sectional diameter was measured on representative slides (to the nearest mm, perpendicular to the involved duct).

Papillary lesions were evaluated histologically and categorized as follows. Papillomas were defined as arborizing fibrovascular stalks lined by at least two layers (myoepithelium and epithelium) of nonatypical epithelial cells, within dilated ductal/cystic space. Papillomas with atypical ductal hyperplasia were defined as papillomas in which the overlying epithelial proliferation showed cytologic atypia, but did not meet cytologic and architectural criteria for ductal carcinoma *in situ*;²⁷ papillomas with ductal carcinoma *in situ* were diagnosed without regard to proposed size criteria.²⁸ Papillary carcinoma was defined as a papillary proliferation lacking myoepithelial cells along papillary fibrovascular stalks. For the purposes of the study, lesions showing focal loss of myoepithelial cells were diagnosed as papillary carcinoma arising in a papilloma, and we used p63, calponin, or smooth muscle myosin heavy-chain immunohistochemical staining to highlight myoepithelial cells in select cases.^{1,28,29} Solid papillary carcinoma was defined as described by Maluf and Koerner.^{1,28–30}

In addition, the extent of epithelial hyperplasia was recorded as mild (epithelium 2–3 layers thick), moderate (epithelium >3 layers thick), or florid (spaces between fibrovascular cores completely filled by epithelial proliferation) using standard criteria,³¹ and the presence of columnar cell change or apocrine metaplasia was also recorded. One nipple duct adenoma with moderate hyperplasia was also included (benign papillary category). The presence of *in situ* or invasive carcinoma elsewhere in the breast specimen, not involving the papillary lesion, was noted.

Preparation of DNA Extracts

Formalin-fixed paraffin-embedded tissue sections were cut at 7 μ m onto glass slides. Using an H&E-stained section as template, areas of papillary lesion were dissected using a clean scalpel blade, then deparaffinized with successive xylene and ethanol

washes. DNA was extracted using the Qiagen DNA Mini Kit (Qiagen, Valencia, CA, USA).

Mutation Screening

The Sequenom MassARRAY system was used to screen for mutations. In brief, this system involves PCR amplification of sequences of interest, followed by primer extension and mass spectrometry (MALDI-TOF MS) as previously detailed.³² Assays were derived from the Sequenom OncoCarta panel (Sequenom, San Diego, CA, USA) and were validated in the laboratory. The majority of cases were first run on a mini panel encompassing mutation assays for *PIK3CA* exon 4 (N545K) and exon 20 (H1047R/L), and *AKT1* exon 2 (E17K); cases without identified mutations were then screened with the full OncoCarta panel. PCR-amplified DNA was cleaned using EXO-SAP (Sequenom), and primer was extended by TYPLEX chemistry, desalted using Clean Resin (Sequenom), and spotted onto SpectroCHIP II matrix chips using the MassARRAY Nanodispenser RS1000 (Sequenom). Chips were run on a Sequenom MassARRAY MALDI-TOF system. Sequenom Typer software and visual inspection were used to interpret mass spectra. Four cases were not screened on Sequenom, but were primarily analyzed by HPLC WAVE and direct sequencing (two cases of papilloma with ductal carcinoma *in situ*, one papillary carcinoma, one nipple duct adenoma, see below). Four cases that failed to spot on the Sequenom chip were assayed similarly (one case each of papilloma, papilloma with hyperplasia, papilloma with atypical ductal hyperplasia, and papilloma with ductal carcinoma *in situ*). There was no difference in size of papillary lesion in cases assayed as wild type vs mutant.

Confirmation of Mutations

PIK3CA exons 9 and 20, and *AKT1* exon 2 were amplified by PCR using primers as previously described, using TAQ polymerase (Expand High Fidelity PCR System, Roche, Indianapolis, IN, USA), with parallel positive and negative controls.²⁰ PCR products were run on a Transgenomic WAVE HPLC system (Transgenomic, Omaha, NE, USA; melting temperature determined empirically for each primer pair).²⁰

Alternatively, mutations were confirmed by direct sequencing on an ABI3130 sequencer using the BigDye Terminator method.

Immunohistochemical Staining

Unstained sections (5 μ m) were prepared on charged glass slides, and stained immunohistochemically for estrogen receptor using standard protocols on a Ventana BenchMark XT automated platform

(Ventana, Tucson, AZ, USA) with rabbit monoclonal antibody SP1 (Ventana). Results were scored semi-quantitatively blinded to gene mutation status (by MLT), including both intensity (0, negative; 1+, weak; 2+, moderate; and 3+, strong) and estimated percentage of nuclei labeled. A product score was calculated by multiplying percent positive nuclei by intensity.

Statistical Analysis

The correlation of *PIK3CA* and/or *AKT1* mutational status to histologic type was analyzed by Fisher's exact test (two-tailed) using the Statview program (SAS Institute, Inc., Cary, NC, USA). A *P*-value of 0.05 was considered significant.

Results

Papillary Lesions

Papillary breast lesions with adequate tissue for analysis were identified from the files of Oregon Health & Science University and Kaiser Permanente Northwest. The study group consisted of 89 papillary lesions, including 61 papillomas without atypia or carcinoma; of these 33 had moderate or florid epithelial hyperplasia. Eighteen papillary lesions had atypia within the epithelial component, including 11 papillomas with atypical ductal hyperplasia, 6 with ductal carcinoma *in situ*, and 1 involved by lobular carcinoma *in situ*. There were 10 papillary carcinomas, including 3 carcinomas arising within papillomas. Three cases had features of the solid variant of papillary carcinoma, including one arising within a papilloma, and two with invasion. Four of the papillary carcinomas were accompanied by an invasive component, including one with tubulopapillary features and one microinvasive (<1 mm invasion). The cross-sectional diameter of papillary lesions ranged from 0.1 to 1.5 cm, average 0.4 cm.

Mutational Analysis

Papillary neoplasms were screened for hotspot point mutations in *AKT1*, *PIK3CA*, *KRAS*, *HRAS*, and *NRAS* using mass spectroscopy. Mutations were confirmed with PCR followed by HPLC assays, or direct sequencing. Eight cases were screened primarily by HPLC, with sequence confirmation. In one case, confirmatory analysis was unsuccessful; in all others there was complete concordance with the initial mass spectroscopy result.

Of 89 tested papillary lesions, we identified *AKT1* E17K mutations in 27 cases (30%, Tables 1 and 2, Figures 1 and 2). A further 21 (24%) cases had *PIK3CA* exon 20 kinase domain mutations, including 18 H1047R and 3 H1047L mutations (Tables 1 and 2, Figures 1 and 2). Interestingly, we identified only four cases (5%) with *PIK3CA* exon 9 helical

Table 1 Mutational analysis of papillary neoplasms

<i>Case</i>	<i>Diagnosis</i>	<i>Mutation</i>
<i>AKT1 exon 2</i>		
5	Papilloma	AKT1 E17K
14	Papilloma	AKT1 E17K
19	Papilloma	AKT1 E17K
25	Papilloma	AKT1 E17K
30	Papilloma	AKT1 E17K
32	Papilloma	AKT1 E17K
33	Papilloma	AKT1 E17K
39	Papilloma	AKT1 E17K
46	Papilloma	AKT1 E17K
48	Papilloma	AKT1 E17K
49	Papilloma	AKT1 E17K
51	Papilloma	AKT1 E17K
52	Papilloma	AKT1 E17K
53	Papilloma	AKT1 E17K
62	Papilloma	AKT1 E17K
6	Papilloma, hyperplasia	AKT1 E17K
40	Papilloma, hyperplasia	AKT1 E17K
47	Papilloma, hyperplasia	AKT1 E17K
60	Papilloma, hyperplasia	AKT1 E17K
67	Papilloma, hyperplasia	AKT1 E17K
15	Papilloma, atypical ductal hyperplasia	AKT1 E17K
23	Papilloma, atypical ductal hyperplasia	AKT1 E17K
34	Papilloma, atypical ductal hyperplasia	AKT1 E17K
74	Papilloma, ductal carcinoma <i>in situ</i>	AKT1 E17K
80	Papilloma, ductal carcinoma <i>in situ</i>	AKT1 E17K
78	Papilloma, ductal carcinoma <i>in situ</i>	AKT1 E17K
86	Papillary carcinoma arising in papilloma	AKT1 E17K
<i>PIK3CA exon 4</i>		
38	Papilloma, hyperplasia	PIK3CA N345K
<i>PIK3CA exon 9</i>		
7	Papilloma	PIK3CA E542K
56	Papilloma	PIK3CA E545K
45	Papilloma, hyperplasia	PIK3CA E545K
89	Papillary carcinoma	PIK3CA E542K
<i>PIK3CA exon 13</i>		
87	Papillary carcinoma, invasive (tubulopapillary)	PIK3CA H701P, E707K, L719V (and NRAS)
<i>PIK3CA exon 20</i>		
1	Papilloma	PIK3CA H1047L
16	Papilloma	PIK3CA H1047R
35	Papilloma	PIK3CA H1047R
58	Papilloma	PIK3CA H1047R
9	Papilloma, hyperplasia	PIK3CA H1047R
18	Papilloma, hyperplasia	PIK3CA H1047R
26	Papilloma, hyperplasia	PIK3CA H1047R
28	Papilloma, hyperplasia	PIK3CA H1047R
29	Papilloma, hyperplasia	PIK3CA H1047R
36	Papilloma, hyperplasia	PIK3CA H1047R
37	Papilloma, hyperplasia	PIK3CA H1047R
50	Papilloma, hyperplasia	PIK3CA H1047R
54	Papilloma, hyperplasia	PIK3CA H1047R
61	Papilloma, hyperplasia	PIK3CA H1047R
65	Papilloma, hyperplasia	PIK3CA H1047R
66	Papilloma, hyperplasia	PIK3CA H1047R
13	Papilloma, atypical ductal hyperplasia,	PIK3CA H1047R
24	Papilloma, atypical ductal hyperplasia	PIK3CA H1047L
69	Papilloma, atypical ductal hyperplasia	PIK3CA H1047R
73	Papilloma, atypical ductal hyperplasia	PIK3CA H1047R
77	Papilloma, atypical ductal hyperplasia	PIK3CA H1047L
<i>RAS family mutations</i>		
76	Papilloma, atypical ductal hyperplasia	HRAS G12D
87	Papillary carcinoma, invasive (tubulopapillary)	NRAS Q61H (and PIK3CA exon 13)

Table 2 Frequency of mutations by type of papillary lesion

Lesion	<i>AKT1</i> (%)	<i>PIK3CA</i> All exons (%)	<i>PIK3CA</i> exon 9 (%)	<i>PIK3CA</i> exon 20 (%)	<i>PIK3CA</i> 4, 13 (%)	<i>RAS</i> (%)	Wild type (%)
<i>Papilloma without atypia</i> (N = 61)	20 (33%)	20 (33%)	3 (5%)	16 (26%)	1 (2%)	0 (0%)	21 (34%)
No epithelial hyperplasia (N = 28)	15 (54%)	6 (21%)	2 (7%)	4 (14%)	0 (0%)		7 (25%)
Moderate-florid hyperplasia (N = 33)	5 (15%)	14 (42%)	1 (3%)	12 (36%)	1 (3%)		14 (42%)
<i>Papilloma with atypia, CIS</i> (N = 18)	6 (33%)	5 (28%)	0 (0%)	5 (28%)	0 (0%)	1 (6%)	6 (33%)
ADH (N = 11)	3 (27%)	5 (45%)		5 (45%)		1 (9%)	2 (19%)
DCIS (N = 6)	3 (50%)	0		0		0	3 (50%)
LCIS (N = 1)	0	0		0		0	1 (100%)
Papillary carcinoma (N = 10)	1 (10%)	2 (20%)	1 (10%)	0 (0%)	1 (10%) ^a	1 (10%)^a	7 (70%)
Total (N = 89)	27 (30%)	27 (30%)	4 (4%)	21 (24%)	2 (3%)	2 (2%)	34 (38%)

ADH: atypical ductal hyperplasia; CIS: carcinoma *in situ*; DCIS: ductal carcinoma *in situ*; LCIS lobular carcinoma *in situ*.

^aIncludes one case with *NRAS* Q61H and *PIK3CA* exon 13 mutations; thus, seven papillary carcinoma cases were wild type.

domain mutations, with two E542K and two E545K (Tables 1 and 2, Figure 1). Other *PIK3CA* mutations included one case with a mutation in exon 4 (N345K, C2 domain), and one case with multiple exon 13 kinase domain mutations (Tables 1 and 2). Invasive breast carcinomas with multiple *PIK3CA* mutations have been previously reported,^{13–15,17–19} though this case appears unique in its mutational profile. Overall, a total of 54 of 89 papillary lesions (61%) had mutations in the *PIK3CA/AKT* pathway.

In addition, two cases had mutations in *RAS* family proteins, with one *HRAS* G12D mutation and one *NRAS* Q61H mutation (Tables 1 and 2, Figure 2). The case with *NRAS* mutation also had *PIK3CA* exon 13 mutations, as listed above. Forty-five cases were screened for *RAS* family mutations, using the full OncoCarta panel, which also encompasses hotspot mutations in *ABL1*, *AKT2*, *BRAF*, *CDK*, *EGFR*, *ERBB2*, *FGFR1*, *FGFR3*, *FLT3*, *KIT*, *JAK2*, *KRAS*, *MET*, *PDGFRA*, and *RET*; no mutations were identified in any of these other genes.

Correlation of Mutation Status with Histopathologic Features

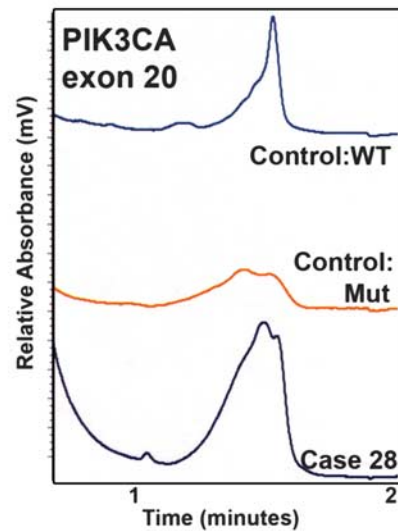
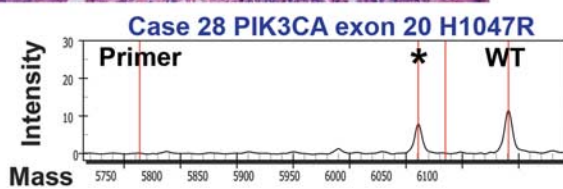
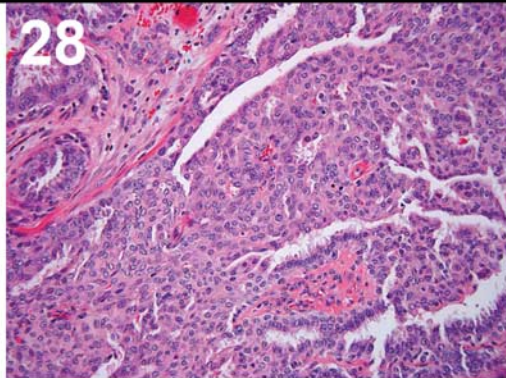
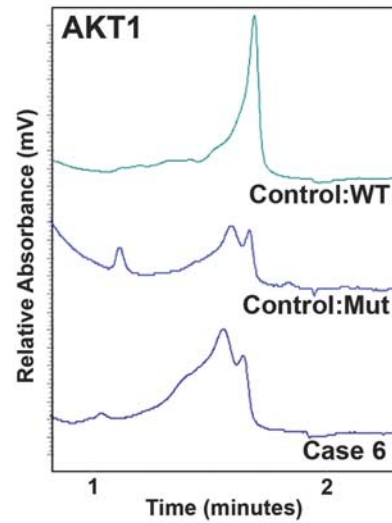
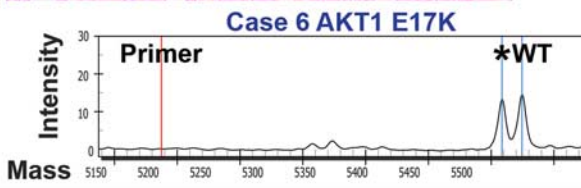
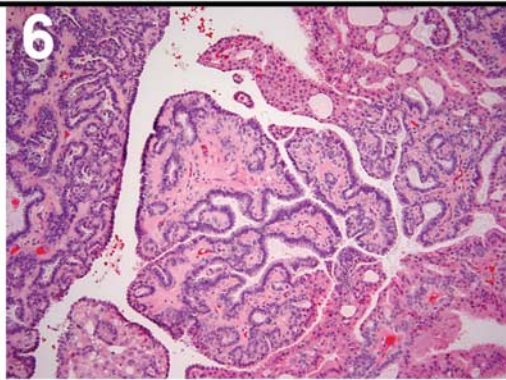
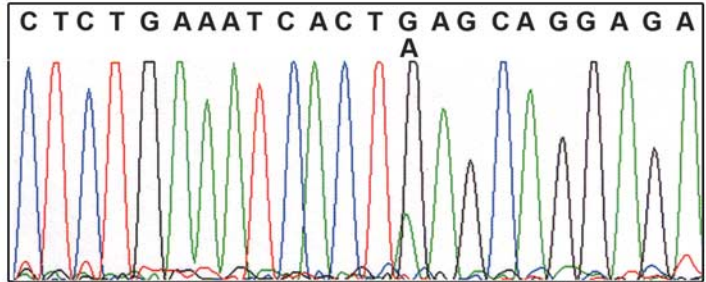
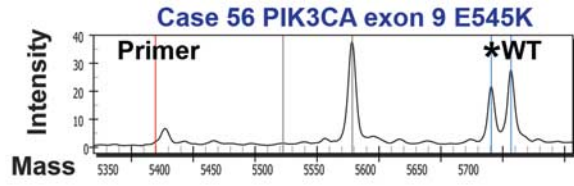
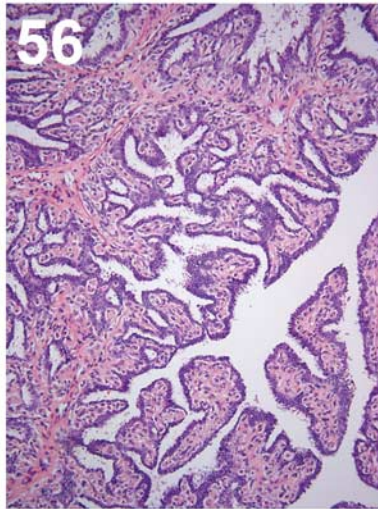
The majority of *AKT1* mutations were identified in papillomas with no more than mild epithelial hyperplasia; there were 15 such cases among the 27 total *AKT1* mutations (56%). Nevertheless, we did identify *AKT1* mutations in papillomas with atypical ductal hyperplasia or ductal carcinoma *in situ* (three cases each). Only a single carcinoma case was found to have an *AKT1* mutation (Tables 1 and 2, Figures 1–3).

In marked contrast to *AKT1*, *PIK3CA* exon 20 mutations were preferentially found in papillomas with moderate to florid epithelial hyperplasia. Of 21 *PIK3CA* exon 20 mutations, 12 were seen in papillomas with hyperplasia (57%). Only four papillomas with no to mild hyperplasia had *PIK3CA*

exon 20 mutations (20%). The difference in frequency of *AKT1* mutations vs *PIK3CA* exon 20 mutations between benign papillomas with and without epithelial hyperplasia was statistically significant ($P = 0.0064$). *PIK3CA* exon 20 mutations were also identified in five cases of papillomas with atypical hyperplasia (5/11, 46%), but none with ductal carcinoma *in situ*. *PIK3CA* exon 20 mutations were not identified in the 10 papillary carcinomas tested (Tables 1 and 2, Figures 1–3). Other *PIK3CA* hotspot mutations (exons 4, 9, 13) were found distributed among papillomas with and without epithelial hyperplasia, and seen in a single case of papillary carcinoma.

RAS family mutations were screened in 45 of the 89 papillary tumors and were found only in carcinoma and papillary neoplasms with epithelial atypia. *RAS* mutations were not identified in any benign papillary lesions.

Interestingly, among the 10 carcinomas, only 3 *PIK3CA/AKT* pathway mutations were identified. The carcinoma with an *AKT1* mutation (case 86) had a background of papilloma, as shown by focal residual myoepithelial cells on p63 and calponin immunohistochemical staining. The case with *PIK3CA* exon 9 mutation was an encapsulated papillary carcinoma. The papillary carcinoma with multiple *PIK3CA* exon 13 mutations and *NRAS* mutation had tubulopapillary features and an extensive invasive component. Seven papillary carcinomas were wild type for tested mutations (six screened with full OncoCarta mutation panel and one with HPLC). The percentage of papillary carcinomas with *PIK3CA/AKT* pathway mutations (3/10, 30%) was considerably lower than in benign or atypical papillary neoplasms. The difference in frequency of combined *PIK3CA* and *AKT1* mutations between papillomas without atypia and papillary carcinomas was statistically significant, despite the relatively small numbers of carcinomas analyzed ($P = 0.0425$).



Correlation of Mutational Status and Histopathologic Features with Estrogen Receptor Expression

A subset of papillary neoplasms was stained immunohistochemically for estrogen receptor and scored for percent nuclear positivity (0–100%) as well as staining intensity (0–3+). A product score was calculated as the percent positive nuclei multiplied by stain intensity. The average product score did not differ among papillary neoplasms with *AKT1* mutation, *PIK3CA* mutation, or wild-type gene status (Table 3). Further, estrogen receptor staining was also analyzed by histopathologic type of papillary neoplasm and showed the expected variability, with strong uniform staining of papillary neoplasms with atypical ductal hyperplasia and low-grade carcinoma, and variable staining in epithelial hyperplasia (Table 3).

Discussion

Because precursors of infiltrating breast carcinoma, such as ductal carcinoma *in situ*, and even atypical ductal hyperplasia, have been shown to exhibit key genetic changes in common with carcinoma,^{20,33–38} we sought to investigate the relationship of papillary lesions to the spectrum of breast premalignant lesions by analyzing kinase mutations. Point mutations in *PIK3CA* and *AKT1* are relatively common in breast carcinoma (average 25 and 4%, respectively),^{10–23} and are located in a small number of ‘hotspots’, many of which have transforming capabilities *in vitro*.^{21,26,39–41} Further, we have previously shown that *PIK3CA* and *AKT1* mutations are present in ductal carcinoma *in situ*.²⁰

In this study, we screened papillary lesions for common mutations in *AKT1* and *PIK3CA*, and found that benign papillomas (defined as papillomas without atypia, ductal carcinoma *in situ* or carcinoma) have an unexpectedly high frequency of *AKT1* mutations (33%, 20/61). We also found *PIK3CA* mutations in 33% of benign papillomas (20/61). Overall, 66% of benign papillary breast lesions had a *PIK3CA* or *AKT1* mutation (40/61). In contrast, papillary carcinomas have a lower rate of mutation in the *PIK3CA*/*AKT1* pathway (30%; $P = 0.0425$). The one example of a papillary carcinoma with an *AKT1* mutation could have arisen within a background of papilloma, as discerned by the presence of focal residual myoepithelial cells. Because most papillary carcinomas lack *PIK3CA* or *AKT1* mutations, it is

unlikely that they could have developed from mutation-positive papillomas. These findings suggest that although some papillary carcinomas may be seen in association with benign papillomas, many other papillary carcinomas may arise through a different molecular pathway. The relationship of papillomas without *PIK3CA* or *AKT1* mutation, if any, to the subsequent evolution of papillary carcinoma or invasive carcinoma remains to be determined.

Likewise, the 30% frequency of papillary neoplasms with *AKT1* (27/89) mutations is far greater than has been reported in the literature for infiltrating breast carcinoma (generally on the order of 4%).^{19,21–23} We also observed a markedly different distribution of *PIK3CA* mutations in papillary neoplasms, as compared with invasive carcinoma. Meta-analysis of the literature shows that approximately 39% of *PIK3CA* mutations in invasive breast carcinoma are exon 9 hotspots (helical domain, E542/5K), 54% are exon 20 mutations (kinase domain, H1047R/L) and 6% are mutations at other sites (<http://www.sanger.ac.uk/genetics/CGP/cosmic/>).^{13–20} In contrast, of *PIK3CA* mutations in papillary neoplasms, we found that the vast majority were exon 20 H1047R/L (77%) with only 15% in exon 9. Further, there was an apparent propensity for *PIK3CA* H1047R/L exon 20 mutations in papillary lesions with moderate to florid epithelial hyperplasia; more than half of the *PIK3CA* exon 20 mutations were found in this histologic category (Figure 3). We previously identified a *PIK3CA* H1047R mutation in one of two tested cases of florid usual ductal hyperplasia, from a patient with invasive ductal carcinoma and ductal carcinoma *in situ* harboring the same mutation.²⁰ The place of usual ductal hyperplasia, if any, along the spectrum of premalignant lesions in breast carcinogenesis is also quite controversial. On the basis of molecular data, primarily loss of heterozygosity and comparative genomic hybridization studies, a number of authors have shown clonal chromosomal aberrations in usual ductal hyperplasia, though they occur at lower frequency, with fewer alterations per lesion, as compared with atypical ductal hyperplasia, ductal carcinoma *in situ*, and invasive carcinomas; other studies have shown identical chromosomal changes in usual ductal hyperplasia and accompanying invasive carcinoma.^{37,42–48} Investigation of activating point mutations in *PIK3CA*, *AKT* and other cell signaling pathways in usual ductal

Figure 1 Morphology and mutational analysis of representative nonatypical papillary neoplasms. Case 56 (top): Papilloma with prominent myoepithelial cells and lack of epithelial hyperplasia, as seen in H&E stain, left panel. Sequenom mutational analysis is at right with mutant peak (*) at *PIK3CA* exon 9 E545K and exon 9 wild-type peak (WT); large peak in middle at solid gray line is wild-type peak for an unrelated assay. Confirmatory sequencing is below. Case 6 (middle): Papilloma with hyperplasia and apocrine metaplasia, as shown at left with H&E stain. Below is Sequenom analysis, showing mutant peak (*) for *AKT1* exon 2 E17K; confirmatory HPLC WAVE analysis is at right. Case 28 (bottom): Papilloma with florid hyperplasia. Left panel shows H&E-stained section. Below is Sequenom mutational analysis with mutant peak (*) at *PIK3CA* exon 20 H1047R. Confirmatory WAVE analysis is at right. (Original magnifications, cases 56 and 6, × 100; case 28, × 200.)

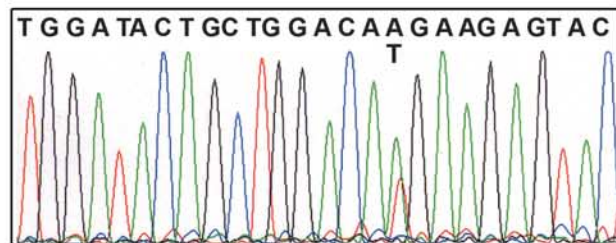
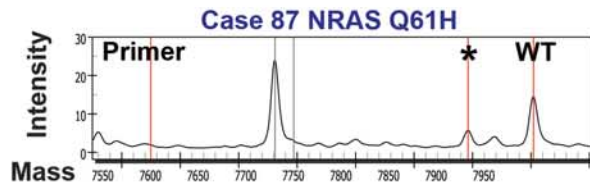
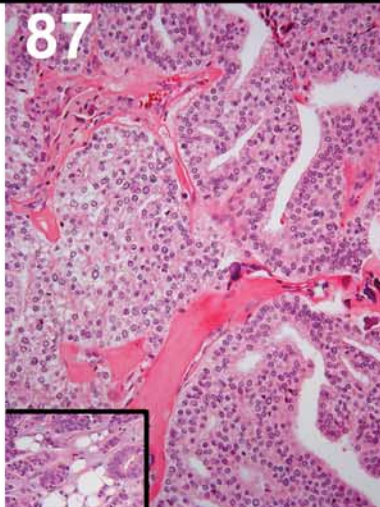
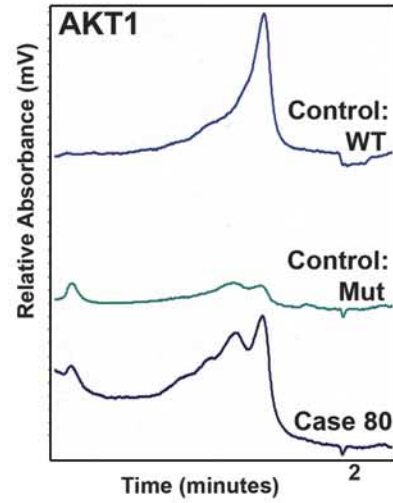
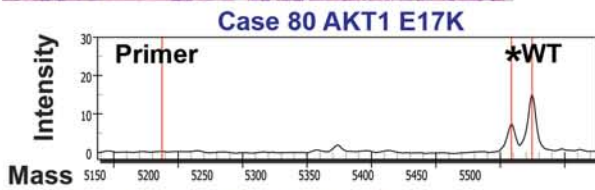
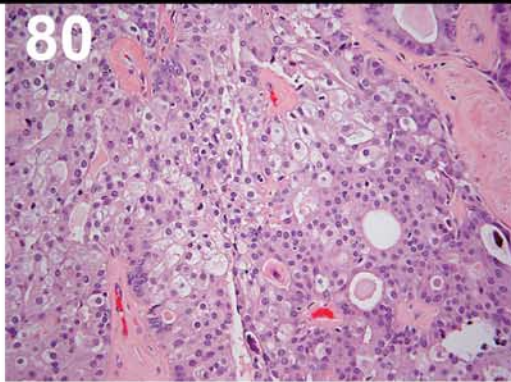
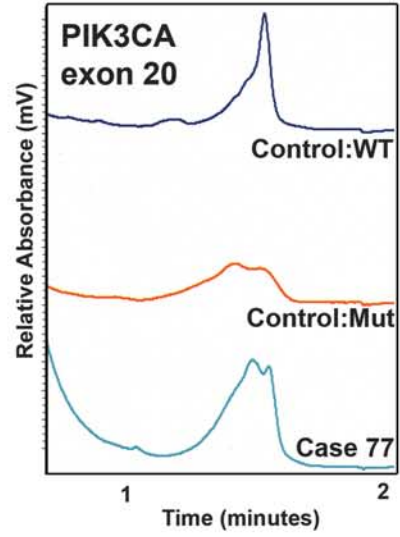
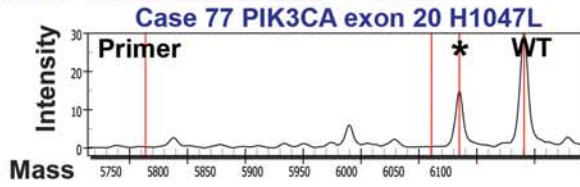
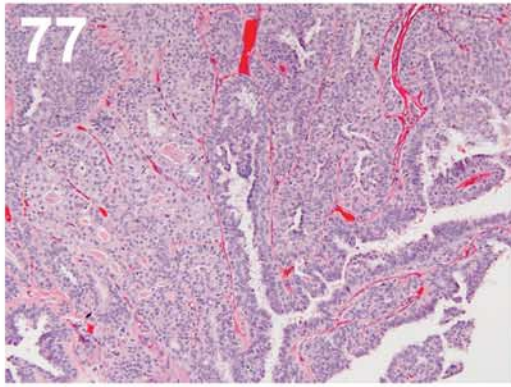


Figure 2 Morphology and mutational analysis of representative papillary neoplasms with atypia or carcinoma. Case 77 (top): Papilloma with atypical ductal hyperplasia. Left panel shows H&E-stained section; below is Sequenom mutational analysis with mutant peak (*) for *PIK3CA* exon 20 H1047L, and exon 20 wild-type peak (WT), with confirmatory HPLC WAVE analysis at right. Case 80 (middle): Papilloma with ductal carcinoma *in situ*. Left panel shows H&E-stained section, below is Sequenom mutational analysis with mutant peak (*) for *AKT1* exon 2 E17K, with confirmatory HPLC WAVE analysis at right. Case 87 (bottom): Papillary carcinoma with invasion. Left panel shows H&E-stained section of papillary carcinoma; inset shows invasive component. At right is Sequenom mutational analysis with mutant peak (*) for *NRAS* Q61. Large peak at right at solid gray line is wild-type peak for an unrelated assay. Confirmatory direct DNA sequencing is shown below, right. (Original magnifications: case 77, $\times 100$; case 80, $\times 200$; case 87, $\times 200$ with $\times 100$ inset.)

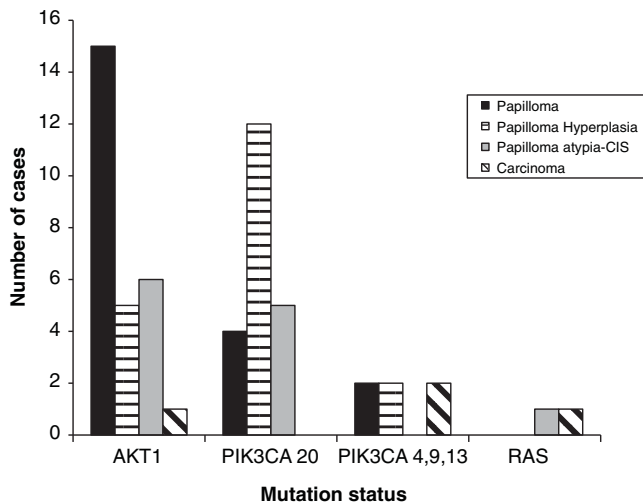


Figure 3 Histopathology of papillary lesions by mutation status. CIS, carcinoma *in situ*.

Table 3 Estrogen receptor immunohistochemical staining

	N	Average estrogen receptor product score (standard deviation)	Cases with diffuse ER staining (%)
By mutation status	34		
AKT1 mutation	10	185 (± 105)	50
PIK3CA mutation	10	220 (± 87)	80
Wild type	14	219 (± 91)	71
By histopathologic type	34		
Papilloma	9	170 (± 100)	56
Papilloma hyperplasia	10	152 (± 86)	30 ^a
Papilloma atypia-carcinoma <i>in situ</i>	8	248 (± 53)	100 ^a
Papillary carcinoma	7	296 (± 11)	100 ^a

Product score = staining intensity (0–3+) multiplied by percent of nuclei staining.

Diffuse estrogen receptor staining defined as >75% of nuclei.

^aStatistically significant difference between papilloma with epithelial hyperplasia and papilloma with atypia-carcinoma *in situ* ($P=0.004$), and between papilloma with epithelial hyperplasia and papillary carcinoma ($P=0.009$). Other pair-wise comparisons, including by mutation status, nonsignificant.

hyperplasia, and other breast precursor lesions such as atypical ductal hyperplasia and columnar cell change, should be instructive in further characterizing the divergent molecular and histologic pathways of breast cancer evolution.

Mutations in small GTP binding proteins of the *RAS* family are relatively rare in breast carcinoma, although *RAS* signaling is frequently upregulated by other mechanisms.^{49,50} We found two cases with *RAS* family hotspot mutations, including one papilloma with atypical ductal hyperplasia and one papillary carcinoma. The *RAS* mutations identified in papillary neoplasms (codon 12, P-loop; codon 61, switch II domain) block GTP turnover and thus lock the protein in the active, GTP-bound state.⁵⁰ Interestingly, in a preliminary report from Esposito *et al*⁵¹, an *HRAS* Q61R (CAG \rightarrow AAG) mutation was noted in 2 of 3 papillary carcinomas, whereas 10 papillomas (4 with atypia or ductal carcinoma *in situ*) were negative for mutations in *HRAS* or *NRAS* codon 61, as well as codons 12/13 of *KRAS*, and the *BRAF* V600E substitution. Taken together, these studies suggest that mutation of *RAS* family members may play a key role in papillary carcinoma; however, confirmation will require study of larger numbers of cases.

In summary, our data suggest that *AKT1* or *PIK3CA* mutation plays a role in the majority of benign papillary neoplasms of the breast. Further, our findings suggest that papillary carcinomas develop along a molecular pathway somewhat divergent from most benign papillary proliferations.

Acknowledgements

We acknowledge expert technical assistance of Carolyn Gendron, Emily Justusson, Dylan Nelson, Cara Poage, Linh Matsumura, Jennifer Podolak, and administrative assistance of Sally Ison and Lynne Rowell. This work was supported in part by a VA Merit Review Grant from the Department of Veterans Affairs (MCH) and by a grant from the Oregon Health & Science University Medical Research Foundation.

Disclosure/conflict of interest

Christopher Corless has received honoraria and research support from Sequenom, Inc. None of the other authors has conflict of interest to declare.

References

- Mulligan AM, O'Malley FP. Papillary lesions of the breast: a review. *Adv Anat Pathol* 2007;14:108–119.

- 2 Noguchi S, Motomura K, Inaji H, *et al*. Clonal analysis of solitary intraductal papilloma of the breast by means of polymerase chain reaction. *Am J Pathol* 1994;144:1320–1325.
- 3 Noguchi S, Aihara T, Koyama H, *et al*. Clonal analysis of benign and malignant human breast tumors by means of polymerase chain reaction. *Cancer Lett* 1995;90:57–63.
- 4 Tsuda H, Takarabe T, Inazawa J, *et al*. Detection of numerical alterations of chromosomes 3, 7, 17 and X in low-grade intracystic papillary tumors of the breast by multi-color fluorescence *in situ* hybridization. *Breast Cancer* 1997;4:247–252.
- 5 Lininger RA, Park WS, Man YG, *et al*. LOH at 16p13 is a novel chromosomal alteration detected in benign and malignant microdissected papillary neoplasms of the breast. *Hum Pathol* 1998;29:1113–1118.
- 6 Di Cristofano C, Mrad K, Zavaglia K, *et al*. Papillary lesions of the breast: a molecular progression? *Breast Cancer Res Treat* 2005;90:71–76.
- 7 Boecker W, Buerger H, Schmitz K, *et al*. Ductal epithelial proliferations of the breast: a biological continuum? Comparative genomic hybridization and high-molecular-weight cytokeratin expression patterns. *J Pathol* 2001;195:415–421.
- 8 Dietrich CU, Pandis N, Teixeira MR, *et al*. Chromosome abnormalities in benign hyperproliferative disorders of epithelial and stromal breast tissue. *Int J Cancer* 1995;60:49–53.
- 9 Komoike Y, Motomura K, Inaji H, *et al*. Diagnosis of ductal carcinoma *in situ* (DCIS) and intraductal papilloma using fluorescence *in situ* hybridization (FISH) analysis. *Breast Cancer* 2000;7:332–336.
- 10 Samuels Y, Velculescu VE. Oncogenic mutations of PIK3CA in human cancers. *Cell Cycle* 2004;3:1221–1224.
- 11 Dillon RL, White DE, Muller WJ. The phosphatidylinositol-3-kinase signaling network: implications for human breast cancer. *Oncogene* 2007;26:1338–1345.
- 12 Bachman KE, Argani P, Samuels Y, *et al*. The PIK3CA gene is mutated with high frequency in human breast cancers. *Cancer Biol Ther* 2004;3:772–775.
- 13 Lee JW, Soung YH, Kim SY, *et al*. PIK3CA gene is frequently mutated in breast carcinomas and hepatocellular carcinomas. *Oncogene* 2005;24:1477–1480.
- 14 Li SY, Rong M, Griew F, *et al*. PIK3CA mutations in breast cancer are associated with poor outcome. *Breast Cancer Res Treat* 2006;96:91–95.
- 15 Liang X, Lau QC, Salto-Tellez M, *et al*. Mutational hotspot in exon 20 of PIK3CA in breast cancer among Singapore Chinese. *Cancer Biol Ther* 2006;5:544–548.
- 16 Maruyama N, Miyoshi Y, Taguchi T, *et al*. Clinicopathologic analysis of breast cancers with PIK3CA mutations in Japanese women. *Clin Cancer Res* 2007;13:408–414.
- 17 Saal LH, Holm K, Maurer M, *et al*. PIK3CA mutations correlate with hormone receptors, node metastasis, and ERBB2, and are mutually exclusive with PTEN loss in human breast carcinoma. *Cancer Res* 2005;65:2554–2559.
- 18 Perez-Tenorio G, Alkhorji L, Olsson B, *et al*. PIK3CA mutations and PTEN loss correlate with similar prognostic factors and are not mutually exclusive in breast cancer. *Clin Cancer Res* 2007;13:3577–3584.
- 19 Stemke-Hale K, Gonzalez-Angulo AM, Lluch A, *et al*. An integrative genomic and proteomic analysis of PIK3CA, PTEN, and AKT mutations in breast cancer. *Cancer Res* 2008;68:6084–6091.
- 20 Dunlap J, Le C, Shukla A, *et al*. Phosphatidylinositol-3-kinase and AKT1 mutations occur early in breast carcinoma. *Breast Cancer Res Treat* 2009; doi:10.1007/s10549-009-0406-1.
- 21 Carpten JD, Faber AL, Horn C, *et al*. A transforming mutation in the pleckstrin homology domain of AKT1 in cancer. *Nature* 2007;448:439–444.
- 22 Bleeker FE, Felicioni L, Buttitta F, *et al*. AKT1(E17K) in human solid tumours. *Oncogene* 2008; doi:10.1038/onc.2008.170.
- 23 Kim MS, Jeong EG, Yoo NJ, *et al*. Mutational analysis of oncogenic AKT E17K mutation in common solid cancers and acute leukaemias. *Br J Cancer* 2008;98:1533–1535.
- 24 Hennessy BT, Smith DL, Ram PT, *et al*. Exploiting the PI3K/AKT pathway for cancer drug discovery. *Nat Rev Drug Discov* 2005;4:988–1004.
- 25 Wymann MP, Marone R. Phosphoinositide 3-kinase in disease: timing, location, and scaffolding. *Curr Opin Cell Biol* 2005;17:141–149.
- 26 Zhao L, Vogt PK. Class I PI3K in oncogenic cellular transformation. *Oncogene* 2008;27:5486–5496.
- 27 Page DL, Rogers LW. Combined histologic and cytologic criteria for the diagnosis of mammary atypical ductal hyperplasia. *Hum Pathol* 1992;23:1095–1097.
- 28 Collins LC, Schnitt SJ. Papillary lesions of the breast: selected diagnostic and management issues. *Histopathology* 2008;52:20–29.
- 29 Rosen PP. Papillary Carcinoma. In: Rosen PP (ed). *Rosen's Breast Pathology*, Vol. 1, 3rd edn. Lippincott Williams & Wilkins: Philadelphia, PA, 2009, pp 429–448.
- 30 Maluf HM, Koerner FC. Solid papillary carcinoma of the breast. A form of intraductal carcinoma with endocrine differentiation frequently associated with mucinous carcinoma. *Am J Surg Pathol* 1995;19:1237–1244.
- 31 Rosen PP. Ductal hyperplasia: usual and atypical. In: Rosen PP (ed). *Rosen's Breast Pathology*, Vol. 1, 3rd edn. Lippincott Williams & Wilkins: Philadelphia, PA, 2009, pp 235–238.
- 32 Pratilas CA, Hanrahan AJ, Halilovic E, *et al*. Genetic predictors of MEK dependence in non-small cell lung cancer. *Cancer Res* 2008;68:9375–9383.
- 33 Ma XJ, Salunga R, Tuggle JT, *et al*. Gene expression profiles of human breast cancer progression. *Proc Natl Acad Sci USA* 2003;100:5974–5979.
- 34 Reis-Filho JS, Lakhani SR. The diagnosis and management of pre-invasive breast disease: genetic alterations in pre-invasive lesions. *Breast Cancer Res* 2003;5:313–319.
- 35 Burstein HJ, Polyak K, Wong JS, *et al*. Ductal carcinoma *in situ* of the breast. *N Engl J Med* 2004;350:1430–1441.
- 36 Simpson PT, Reis-Filho JS, Gale T, *et al*. Molecular evolution of breast cancer. *J Pathol* 2005;205:248–254.
- 37 Arpino G, Laucirica R, Elledge RM. Premalignant and *in situ* breast disease: biology and clinical implications. *Ann Intern Med* 2005;143:446–457.
- 38 Moulis S, Sgroi DC. Re-evaluating early breast neoplasia. *Breast Cancer Res* 2008;10:302.
- 39 Samuels Y, Wang Z, Bardelli A, *et al*. High frequency of mutations of the PIK3CA gene in human cancers. *Science* 2004;304:554.
- 40 Isakoff SJ, Engelman JA, Irie HY, *et al*. Breast cancer-associated PIK3CA mutations are oncogenic in mammary epithelial cells. *Cancer Res* 2005;65:10992–11000.

- 41 Ikenoue T, Kanai F, Hikiba Y, *et al*. Functional analysis of PIK3CA gene mutations in human colorectal cancer. *Cancer Res* 2005;65:4562–4567.
- 42 O’Connell P, Pekkel V, Fuqua SA, *et al*. Analysis of loss of heterozygosity in 399 premalignant breast lesions at 15 genetic loci. *J Natl Cancer Inst* 1998;90:697–703.
- 43 Werner M, Mattis A, Aubele M, *et al*. 20q13.2 amplification in intraductal hyperplasia adjacent to *in situ* and invasive ductal carcinoma of the breast. *Virchows Arch* 1999;435:469–472.
- 44 Aubele MM, Cummings MC, Mattis AE, *et al*. Accumulation of chromosomal imbalances from intraductal proliferative lesions to adjacent *in situ* and invasive ductal breast cancer. *Diagn Mol Pathol* 2000;9:14–19.
- 45 Allred DC, Mohsin SK, Fuqua SA. Histological and biological evolution of human premalignant breast disease. *Endocr Relat Cancer* 2001;8:47–61.
- 46 Gong G, DeVries S, Chew KL, *et al*. Genetic changes in paired atypical and usual ductal hyperplasia of the breast by comparative genomic hybridization. *Clin Cancer Res* 2001;7:2410–2414.
- 47 Jones C, Merrett S, Thomas VA, *et al*. Comparative genomic hybridization analysis of bilateral hyperplasia of usual type of the breast. *J Pathol* 2003;199:152–156.
- 48 Yu Q, Niu Y, Yu Y, *et al*. Analysis of the progression of intraductal proliferative lesions in the breast by PCR-based clonal assay. *Breast Cancer Res Treat* 2009;114:433–440.
- 49 Malaney S, Daly RJ. The ras signaling pathway in mammary tumorigenesis and metastasis. *J Mammary Gland Biol Neoplasia* 2001;6:101–113.
- 50 Karnoub AE, Weinberg RA. Ras oncogenes: split personalities. *Nat Rev Mol Cell Biol* 2008;9:517–531.
- 51 Esposito N, Nikiforova M, Nikiforov Y, *et al*. Mutational Profile of RAS and BRAF genes in papillary lesions of the breast: identification of a common HRAS mutation in intracystic papillary carcinoma. *Mod Pathol* 2008;21:47A.