

Diagnosis of Gastrointestinal Stromal Tumors: A Consensus Approach

CHRISTOPHER D.M. FLETCHER, MD, FRCPath,
JULES J. BERMAN, MD, PhD, CHRISTOPHER CORLESS, MD, PhD,
FRED GORSTEIN, MD, JERZY LASOTA, MD, PhD,
B. JACK LONGLEY, MD, MARKKU MIETTINEN, MD,
TIMOTHY J. O'LEARY, MD, PhD, HELEN REMOTTI, MD,
BRIAN P. RUBIN, MD, PhD, BARRY SHMOOKLER, MD,
LESLIE H. SOBIN, MD, AND SHARON W. WEISS, MD

As a result of major recent advances in understanding the biology of gastrointestinal stromal tumors (GISTs), specifically recognition of the central role of activating *KIT* mutations and associated *KIT* protein expression in these lesions, and the development of novel and effective therapy for GISTs using the receptor tyrosine kinase inhibitor STI-571, these tumors have become the focus of considerable attention by pathologists, clinicians, and patients. Stromal/mesenchymal tumors of the gastrointestinal tract have long been a source of confusion and controversy with regard to classification, line(s) of differentiation, and prognostication. Characterization of the *KIT* pathway and its phenotypic implications has helped to resolve some but not all of these issues. Given the now critical role of accurate and reproducible pathologic diagnosis in ensuring appropriate treatment for patients with GIST, the National Institutes of

The recent introduction of a new targeted therapy, STI-571 (imatinib mesylate [Gleevec]; Novartis, Basel, Switzerland)—a receptor tyrosine kinase inhibitor that inhibits the activated *KIT* protein (discussed in detail elsewhere in this issue of HUMAN PATHOLOGY) and that for the first time provides an effective treatment for recurrent or metastatic gastrointestinal stromal tumors (GISTs) (sarcomas)—has focused attention on this formerly “orphan” group of neoplasms. The introduction of phase II and phase III clinical trials of STI-571, now

Health convened a GIST workshop in April 2001 with the goal of developing a consensus approach to diagnosis and morphologic prognostication. Key elements of the consensus, as described herein, are the defining role of *KIT* immunopositivity in diagnosis and a proposed scheme for estimating metastatic risk in these lesions, based on tumor size and mitotic count, recognizing that it is probably unwise to use the definitive term “benign” for any GIST, at least at the present time. HUM PATHOL 33:459-465. Copyright 2002, Elsevier Science (USA). All rights reserved.

Key words: gastrointestinal stromal tumor, sarcoma, diagnosis, guidelines, *KIT*, CD117.

Abbreviations: GI, gastrointestinal; GIST, gastrointestinal stromal tumor; GANT, gastrointestinal autonomic nerve tumor; SMA, smooth-muscle actin.

known as Gleevec, in both the United States and Europe has stimulated considerable interest in these tumors (and in the as-yet unfulfilled possibility that the same therapy might be beneficial in other solid tumor types). Because of a lack of effective therapeutic options for GISTs once they relapse, these lesions truly have been a neglected area (except perhaps in the pathology literature) and have been regarded as very rare. Based on the most recently published National Cancer Institute's SEER data¹ (which antedate recognition of the defining role of *KIT* positivity in GISTs), sarcomas account for 2.2% of gastric cancers, 13.9% of small bowel cancers, and 0.1% of all colorectal cancers. However, the remarkably rapid accrual of patients to the aforementioned trials (as well as the unexpected level of patient interest in these trials) has led to a revision of informal estimates of the annual incidence of clinically detected new cases of GIST in the United States from perhaps 300 to 500/year to more like 5000 to 6000/year.

This major clinical advance has been driven by the relatively recent recognition of the central role of activating *KIT* mutations in the pathogenesis of GISTs,²⁻⁴ which in turn usually lead to expression of *KIT* protein (CD117) and hence to the recognition of a new and reliable phenotypic marker for these neoplasms.^{5,6} This has led to a major reappraisal of the classification of spindle cell tumors in the gastrointestinal (GI) tract over the past 3–4 years, as described later. More important, however, the therapeutic relevance of *KIT* activation in GISTs has generated a requirement for repro-

From the Department of Pathology, Brigham and Women's Hospital and Harvard Medical School, Boston MA; Cancer Diagnosis Program, National Cancer Institute, National Institutes of Health, Bethesda, MD; Department of Pathology, Oregon Health Sciences University, Portland, OR; Department of Pathology, Thomas Jefferson University, Philadelphia, PA; Departments of Soft Tissue Pathology, Cellular Pathology, and Genetics & Gastrointestinal Pathology, Armed Forces Institute of Pathology, Washington, DC; Departments of Pathology & Dermatology, College of Physicians & Surgeons, Columbia University, New York, NY; Department of Pathology, University of Washington Medical Center, Seattle, WA; Department of Pathology, Suburban Hospital, Bethesda, MD; and Department of Pathology & Laboratory Medicine, Emory University Hospital, Atlanta, GA. Accepted for publication January 28, 2002.

This proposal represents the consensus view of the authors and does not represent National Institutes of Health policy. The authors have all read and concur with the statements included in the manuscript.

Address correspondence and reprint requests to Christopher D.M. Fletcher, MD, FRCPath, Department of Pathology, Brigham and Women's Hospital, 75 Francis Street Boston, MA 02115.

Copyright 2002, Elsevier Science (USA). All rights reserved.
0046-8177/02/3305-0003\$35.00/0
doi:10.1053/hupa.2002.123545

ducible diagnostic criteria for these tumors, both for selection of rational therapy and as a key criterion for eligibility to be entered into trials of STI-571. To address these important goals, the National Institutes of Health convened a GIST Workshop in April 2001, a brief summary of which has already been published.⁷ This consensus report is a product of that workshop.

HISTORICAL OVERVIEW

The way(s) in which spindle cell tumors, and subsequently epithelioid tumors, apparently arising from stromal/mesenchymal components of the GI tract have been perceived and classified over the past 50 to 60 years has been the subject of detailed reviews elsewhere,⁸⁻¹¹ and thus only a brief summary is provided here.

Following seminal descriptions in the 1940s by Stout and others, stromal tumors arising in the GI tract were generally regarded as smooth-muscle neoplasms (using the terms "leiomyoma," "leiomyosarcoma," "leiomyoblastoma," and "bizarre leiomyoma") until at least the late 1960s. The application of electron microscopy to the study of human tumors in the late 1960s and early 1970s revealed that relatively few of these neoplasms showed convincing ultrastructural evidence of smooth-muscle differentiation. With the introduction of immunohistochemistry in the early 1980s, it was also soon appreciated that many of these lesions (albeit with the exact proportion often argued) lacked the immunophenotypic features of smooth-muscle differentiation, and this led Mazur and Clark in 1983¹² to introduce the more generic designation "stromal tumor." These same authors, along with many others, realized that at least some stromal tumors of the GI tract expressed neural crest antigens such as S-100 protein and neuron-specific enolase and those engaged in electron microscopy studies also noted that some cases showed Schwannian or neuroaxonal differentiation. A subset of such lesions that showed clear ultrastructural evidence of autonomic neuronal differentiation was designated "plexosarcoma" by Herrera et al in 1984¹³ and subsequently became better known as gastrointestinal autonomic nerve tumors (GANTs).¹⁴

By the early 1990s, there was considerable confusion as to the line or lines of differentiation ("histogenesis") shown by these stromal tumors, and there was a sense that some were truly myogenic (smooth muscle), some were neural, some seemed to show bidirectional differentiation, and some had a "null" phenotype.¹⁵ The relative proportions in these categories were disputed, mainly as a consequence of the different results published in various immunohistochemical studies. Soon thereafter, it became appreciated that a significant proportion of these lesions of both spindle cell and epithelioid type showed CD34 immunopositivity,^{16,17} and this ubiquitous antigen was promulgated as a more reproducible marker of GISTs. However, it became evident over the succeeding few years that no more than 60% to 70% of GISTs (at most) are CD34

immunopositive, and furthermore, Schwann cell neoplasms and a proportion of true smooth-muscle tumors also show CD34 positivity. Thus, in the later 1990s there were 2 somewhat dichotomous approaches. The first approach was to pragmatically lump all mesenchymal tumors of the GI tract under the generic heading of "GIST" either without regard for immunophenotypic differences or perhaps noting these differences in passing. This approach, although popular, suffered from including true leiomyomas and schwannomas under the rubric of GIST. The second approach was to attempt to strictly identify a group of mesenchymal tumors that excluded true leiomyomas and schwannomas and that also had certain common histopathologic properties. Although this approach was closer to current thinking, diagnostic reproducibility was flawed because of varying levels of expertise and the lack of a sensitive and relatively specific diagnostic marker that could reliably identify nonmyogenic, nonschwannian stromal tumors.

This confused (and confusing) situation was ripe for clarification and restructuring. Hence the revelations concerning *KIT* mutations and *KIT* expression²⁻⁶ have rapidly transformed this field. Without recapitulating in excessive detail what has been reviewed elsewhere,⁹⁻¹¹ it is now appreciated that *KIT* immunoreactivity, in the specific context of mesenchymal lesions of the GI tract, defines a group of tumors showing differentiation toward (or being derived from) interstitial cells of Cajal.^{5,18} These cells, also sometimes known as GI pacemaker cells, form the interface between the autonomic innervation of bowel wall and the smooth muscle itself. They have immunophenotypic and ultrastructural features of both smooth muscle and neuronal differentiation in varying degrees and serve to regulate peristalsis. The overwhelming majority of mesenchymal lesions of the GI tract seem now to fall into this "histogenetic" category. In contrast, the less common true smooth-muscle neoplasms and Schwann cell neoplasms of the GI tract lack *KIT* mutations and do not overexpress *KIT* protein (CD117) as detected immunohistochemically. Based on what is now known of the interstitial cells of Cajal, it is not surprising that carefully defined examples of GANT share a molecular genetic identity with conventional spindle and epithelioid cell forms of GIST, and hence GANT most likely no longer warrants designation as a separate entity.¹⁹

DIAGNOSIS OF GIST

The question now arises as to whether this more rational basis for classifying stromal/mesenchymal neoplasms of the GI tract, which is underpinned and defined by the molecular genetic identification of the role of *KIT* should be adopted in routine daily practice. Stated simply, should the term "gastrointestinal stromal tumor" be limited specifically to that group of intra-abdominal mesenchymal lesions showing immunopositivity for *KIT*? As a corollary to the foregoing, should *KIT* immunostaining become the gold standard for the

TABLE 1. Immunohistochemical Schema for the Differential Diagnosis of Spindle Cell Tumors of the GI Tract

	KIT (CD117)	CD34	SMA	Desmin	S-100
GIST	+	+ (60% to 70%)	+ (30% to 40%)	Very rare	5%+
Smooth muscle tumor	—	+ (10% to 15%)	+	+	Rare
Schwannoma	—	+ (usually Antoni B)	—	—	+
Fibromatosis	Disputed*	Rare	+	Rare cells	—

Abbreviation: SMA, smooth muscle actin.

*Most, but not all authors report that fibromatoses are negative for KIT.

diagnosis of GIST? This would help overcome much of the confusion described earlier, would allow a more reproducible and more readily applied classification scheme for spindle cell tumors of the GI tract (Table 1), and might facilitate the development of more effective means of prognostication, at least for some subsets of GI stromal/mesenchymal neoplasms.

Given the now evident clinical and therapeutic importance of KIT expression in this context, combined with the remarkably consistent results obtained by most groups working in this field using readily available commercial antibodies to KIT (CD117) on paraffin-embedded sections, it is the majority view of this group of authors that indeed the term “GIST” should apply only to neoplasms displaying KIT immunopositivity with very rare exceptions. Such exceptions might include lesions with typical cytoarchitectural features of GIST but which (1) appear to be immunohistochemically inert (e.g., due to some type of fixation artefact, excessive heat during section drying, or very prolonged storage of unstained slides), (2) are KIT negative due to sampling error (e.g., very small needle biopsies showing normal internal control staining for other antigens from tumors in which KIT staining is focal in distribution), (3) have (in rare cases) ceased to express KIT due to some form of clonal evolution, perhaps following STI-571 therapy, or (4) in the very small percentage (<2%) of otherwise typical tumors that lack either *KIT* mutations and/or *KIT* overexpression. Tumors in these exceptional categories should be labeled “spindle cell (or epithelioid) stromal neoplasm most consistent with GIST.” Whether or not KIT positivity should be *required* for a diagnosis of GIST is more contentious. The clinicopathologic features of many GISTs are so characteristic that some experts may feel secure in making the diagnosis without immunohistochemistry. However, we feel that KIT immunostains should be performed as a confirmatory (if not diagnostic) measure to facilitate meaningful diagnostic standardization and determination of eligibility for STI-571 therapy. Parenthetically, as with all immunostains, KIT immunopositivity is not in isolation grounds for diagnosing GIST and must always be interpreted in light of the morphologic findings. A few other sarcoma types may show KIT positivity,²⁰ but more often, unexpected KIT positivity (e.g., in a pleomorphic spindle cell sarcoma) is the result of a technical artifact.

The diagnosis of GIST is often suspected histologically, because the majority of cases have remarkably uniform appearances falling into 1 of 3 categories:

spindle cell type (70%) (Fig 1), epithelioid type (20%) (Fig 2), or mixed type (Fig 3). Perhaps 5% of lesions show a variably prominent myxoid stroma, some cases (especially in the small intestine) show a nested paraganglioma-like (Fig 4) or carcinoid-like growth pattern, and only a very small minority of cases (<2% to 3%) show notable cytologic pleomorphism. The latter feature, however, is more often suggestive of a true smooth-muscle neoplasm, which would tend to have more brightly eosinophilic cytoplasm. The prognostic relevance of cell type seems limited, although in the past it was often suggested that the mitotic threshold for malignancy was lower in epithelioid tumors than in spindle cell tumors.

GISTs of spindle cell type are composed typically of relatively uniform eosinophilic cells arranged in short fascicles or whorls. The tumor cells have paler eosinophilic cytoplasm than smooth muscle neoplasms, often with a fibrillary, syncytial appearance (i.e., with indistinct cell margins); nuclei tend to be uniform in appearance and more ovoid or shorter than those of a smooth-muscle cytoplasm, often with vesicular chromatin. Striking juxtenuclear cytoplasmic vacuoles are seen in up to 5% of all cases (Fig 5) and are particularly a feature of gastric tumors; in the past this was mistakenly believed to be a feature of smooth-muscle differentiation. Nuclear palisading is often seen, as are stromal lymphocytes and microcystic stromal degeneration (reminiscent of a schwannoma). Stromal collagen is minimal in most cases, but delicate thin-walled vessels may be prominent, and stromal hemorrhage is a common feature of these tumors.

GISTs of epithelioid type are composed of rounded cells with variably eosinophilic or clear cytoplasm. In cases with clear cytoplasm, often “retracted” eosinophilic cytoplasm (simulating inclusions) can be seen around or adjacent to the tumor cell nuclei. Epithelioid lesions, similar to spindle cell lesions, tend to have uniform round-to-ovoid nuclei with vesicular chromatin, and this subset of tumors shows a nested architecture more often than spindle cell cases, enhancing the risk of confusion with an epithelial or melanocytic neoplasm. Lesions of mixed cell type may exhibit an abrupt transition between spindle cell and epithelioid areas (necessitating careful sampling if both patterns are to be recognized), or may have a complex comingling of these cell types throughout, leading to an “intermediate” ovoid cytologic appearance.

A subset of cases (approximately 10% to 20%) of either spindle cell or epithelioid type, most notably

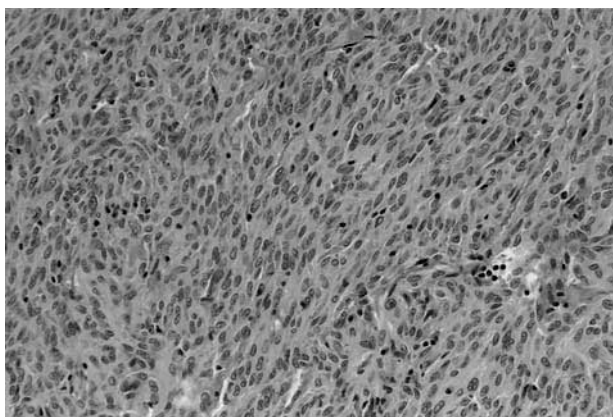


FIGURE 1. GIST, spindle cell type. Note the usual cytologic uniformity and syncytial-appearing eosinophilic cytoplasm.

when located in the small bowel, are associated with stromal skeinoid fibers (Fig 6). These are hyaline or fibrillary brightly eosinophilic structures, seemingly composed of nodular tangles of collagen fibers,²¹ which typically show bright PAS positivity and are globular or more elongated in appearance. Although formerly be-

lieved to correlate with neural differentiation, these structures now appear to have no histogenetic significance.

IMMUNOPHENOTYPE

Aside from consistent positivity for KIT (CD117), about 60% to 70% of GISTs show immunopositivity for CD34, 30% to 40% show immunopositivity for smooth-muscle actin (SMA), and around 5% show immunopositivity for S-100 protein. None of the latter antigens are specific for GIST (see Table 1). Desmin positivity in true KIT-positive GISTs is extremely uncommon (1% to 2% of cases) and is invariably focal, with positivity in only a small number of tumor cells. The immunophenotype of true KIT-positive GISTs varies to some degree by location, with CD34 positivity seen most consistently in colorectal and esophageal lesions and SMA positivity seen most often in small bowel tumors.²² Because neither of these antigens is diagnostically specific, such variation has only limited relevance in routine clinical practice.

In terms of KIT immunostaining, there is some

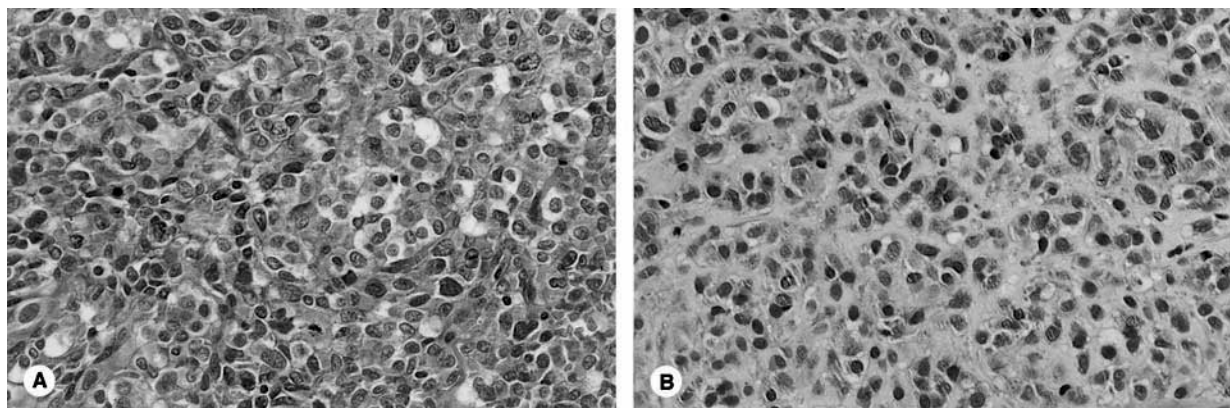


FIGURE 2. GIST, epithelioid type. Epithelioid lesions have variably eosinophilic-to-clear cytoplasm (A) and quite often have a loose myxoid stroma (B).

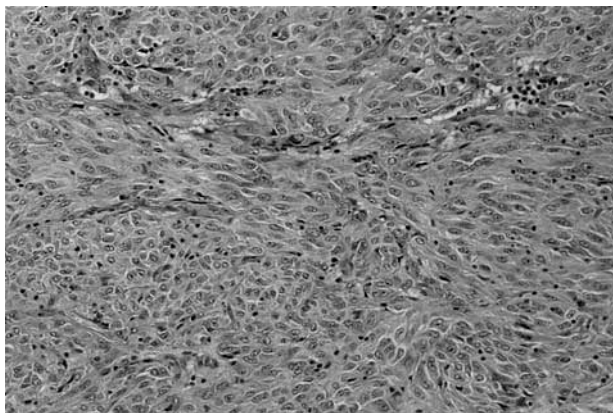


FIGURE 3. GIST, mixed cell type. Some lesions show both spindle cell and epithelioid features.

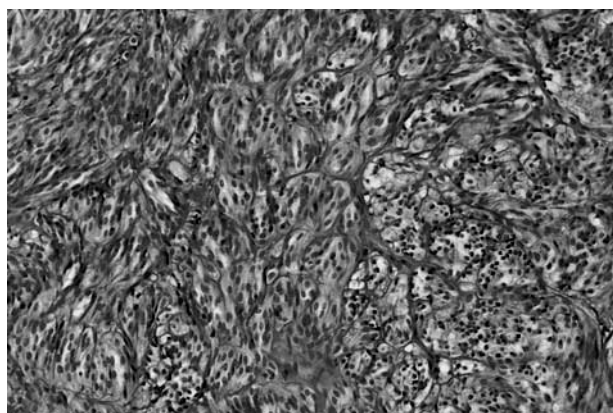


FIGURE 4. GIST. Lesions with a nested paraganglioma-like appearance are usually located in the small intestine.

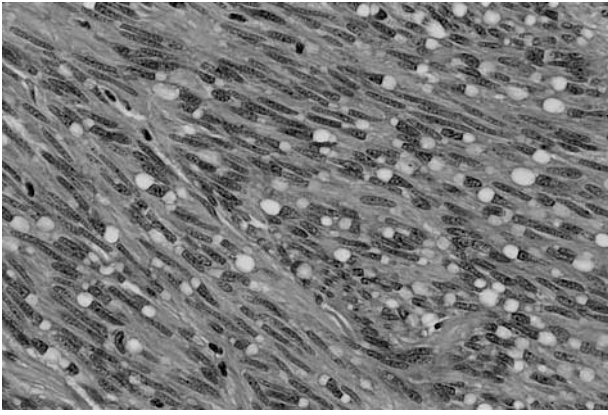


FIGURE 5. GIST. Spindle cell lesions with prominent paranuclear cytoplasmic vacuoles are virtually confined to the stomach.

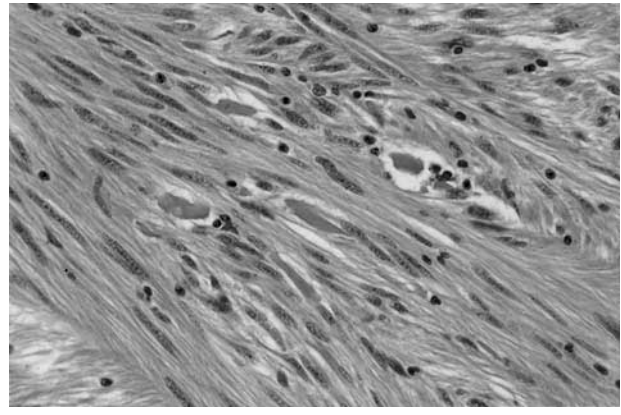


FIGURE 6. GIST. This small bowel lesion shows numerous eosinophilic hyaline skeinoid fibers.

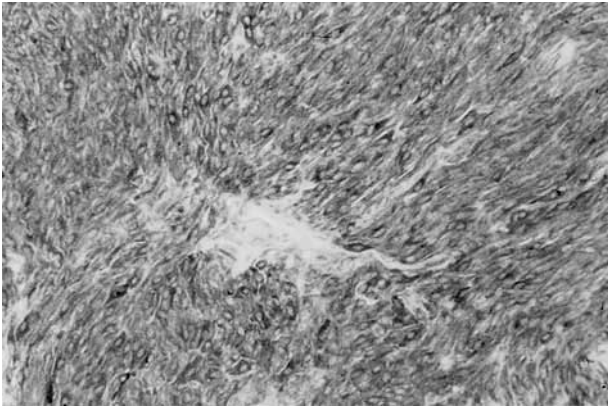


FIGURE 7. KIT staining in GIST. Most cases show diffuse, strong, cytoplasmic positivity in the majority of tumor cells.




FIGURE 8. KIT staining in GIST. A significant subset of cases show a combination of cytoplasmic and dot-like immunopositivity.

variability in pattern, but most GISTs show unequivocal diffuse, strong cytoplasmic positivity (Fig 7). Up to 50% of cases show cytoplasmic dot-like (so-called “golgi pattern”) staining which often coexists with the more diffuse cytoplasmic pattern (Fig 8). Occasional cases show only the dot-like staining pattern (Fig 9). It seems possible that these varied staining patterns correlate with different types of *KIT* mutation, and this is currently being studied. Whereas most GISTs show KIT positivity in 90% of tumor cells, a small minority show more focal staining in as few as 5% to 20% of tumor cells. The therapeutic relevance of such apparently more limited expression is as yet uncertain, but this may certainly give rise to sampling error in small biopsy samples, as mentioned earlier. Given the potential therapeutic significance of KIT immunopositivity and hence the desirability of avoiding false-positive or false-negative results, it is important to carefully retitrate each new batch of the most widely used polyclonal KIT antibodies (using appropriate positive and negative controls). Stromal mast cells almost invariably also serve as a valuable internal positive control.

ANATOMIC LOCATION

GISTs may arise anywhere in the tubular GI tract, from the esophagus to the rectum. In addition, it has

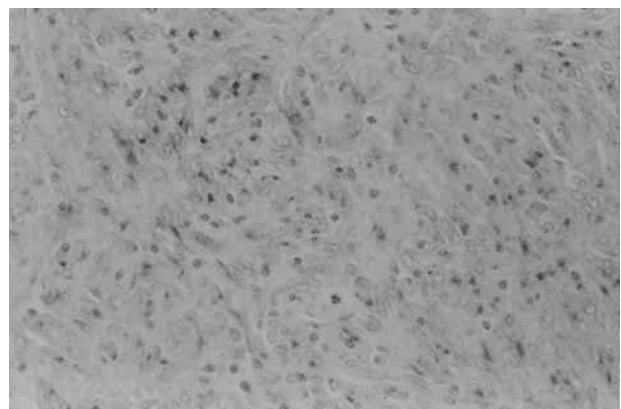


FIGURE 9. KIT staining in GIST. Rare cases show only dot-like reactivity in the tumor cell cytoplasm.

been appreciated in recent years that identical lesions also occur in extra-GI locations, principally mesentery, omentum, and retroperitoneum,²³⁻²⁵ and the demonstration of KIT expression in these lesions has helped validate their existence, particularly in exceptional sites such as the gallbladder²⁶ or bladder.²⁷ In terms of more detailed distribution,²⁸ 50% to 60% of lesions arise in the stomach, 20% to 30% in the small bowel,^{29,30} 10% in the large bowel,^{31,32} 5% in the esophagus,³³ and 5% elsewhere in the abdominal cavity. There are some site-specific variations in morphology. Epithelioid lesions occur far more often in the stomach than elsewhere,³⁴ whereas spindle cell lesions of the small bowel have a particular tendency to show a paraganglioma-like organoid appearance and to contain skeinoid fibers.^{21,34} Prognosis in GISTs also depends to some extent on anatomic site,^{8,34} but the degree to which this relates to tumor size and/or histologic subtype has not been clear. More recent data suggest that anatomic location is a prognostic factor independent of tumor size, mitotic rate, and patient age,²⁸ with a trend for small bowel tumors to have the worst prognosis and esophageal tumors the best, but the basis for these differences remains uncertain. Some authors have a different viewpoint; for example, regarding most esophageal and colonic lesions as malignant.¹¹ Earlier studies regarding esophageal lesions as less aggressive included smooth-muscle tumors as well as GISTs²⁸; it appears that KIT-positive esophageal lesions have an especially poor outcome.³³ Unfortunately, site is not reliably predictive of outcome on an individual case basis.

PREDICTION OF BEHAVIOR

Criteria for distinguishing benign from malignant GISTs, or at least to identify those lesions more likely to metastasize, have been sought, analyzed, and disputed for many years. Many parameters have been proposed—more than can usefully be reviewed herein—but the morphologic features that have gained greatest acceptance as being predictive of outcome are mitotic rate and tumor size.^{8,9,11,35-37} The problem that has persisted (and that still remains unresolved) is that whereas these indices correlate with a *relative risk* of malignant behavior, the fact remains that lesions that are very small (even <2 cm) and lesions with very low mitotic rates (even <5 per 50 high-power fields) occasionally metastasize. Furthermore, this phenomenon of unpredictability is not exceptionally rare in GISTs and has led to the use of terms such as “uncertain malignant potential.” Factors such a mucosal invasion, tumor necrosis, and high cellularity have shown a statistical association with malignant behavior in at least some studies, but this has been poorly reproducible, and these parameters have not proved to be consistently useful on an individual-case basis.

In fact, an increasing number of centers are reluctant to use the term “benign” for any GIST, with the possible (but disputed) exception of very small lesions

(usually <1 cm) found incidentally during abdominal surgery for other reasons. With prolonged follow-up, it appears that almost any GIST presenting with clinical symptoms or signs leading to treatment has the potential to behave in a malignant fashion. Having said this, no more than 50% of primary localized GISTs relapse within the first 5 years of follow-up,³⁷ but the situation at 10 years is much less clear,^{28,36} likely reflecting different populations under study. What is absolutely clear is that, to date, if these tumors recur locally within the peritoneal cavity or give rise to hepatic metastasis (the 2 most common forms of first relapse for GIST), then the prognosis is almost invariably poor, albeit sometimes over a prolonged time scale.

This complex and unsatisfactory situation has led many authors to attempt to define more objective indices of likely behavior, including immunohistochemical markers of cell proliferation (e.g., Ki-67, MIB-1, PCNA), DNA flow cytometry, image analysis, and assessment of nucleolar organizer regions. But none of these has been shown to consistently improve on more conventional morphologic parameters and, perhaps most important, none of these approaches has proven useful on an individual-case basis, the true reflection of clinical reality.

Although some experts disagree and maintain that at least some benign lesions can be accurately identified on morphologic grounds alone, it seems most prudent to develop a scheme based on risk assessment, rather than try to define strict criteria to separate benign from malignant (which appears to be a practical impossibility at the current time).^{24,38} Thus, instead, one would indicate for a given GIST its risk (low, intermediate, or high) of pursuing an aggressive clinical course, recognizing that some subset of cases (hopefully <10%) will behave in an unpredicted or unexpected fashion and that no lesion can be definitively labeled as benign. Suggested definitions for these risk categories are shown in Table 2. These definitions are based on the

TABLE 2. Proposed Approach for Defining Risk of Aggressive Behavior in GISTs

	Size*	Mitotic Count†
Very low risk	<2 cm	<5/50 HPF
Low risk	2–5 cm	<5/50 HPF
Intermediate risk	<5 cm	6–10/50 HPF
	5–10 cm	<5/50 HPF
High risk	>5 cm	>5/50 HPF
	>10 cm	Any mitotic rate
	Any size	>10/50 HPF

Abbreviation: HPF, high-power field.

*Size represents the single largest dimension. Admittedly this may vary somewhat between prefixation and postfixation and between observers. There is a general but poorly defined sense that perhaps the size threshold for aggressive behavior should be 1 to 2 cm less in the small bowel than elsewhere.

†Ideally, mitotic count should be standardized according to surface area examined (based on size of high-power fields), but there are no agreed-on definitions in this regard. Despite inevitable subjectivity in recognition of mitoses and variability in the area of high power fields, such mitotic counts still prove useful.

cumulative experience of the authors of these guidelines and represent a majority view. We hope and believe that this system can be improved on and that more effective prognostic parameters can be established, perhaps on the basis of molecular genetic or mutational analysis (the promise of which is uncertain and unfulfilled at this time). Nevertheless, we believe that these risk categories as currently defined should prove clinically useful, and in light of the uncertainties expressed herein and the well-recognized tendency of these troublesome tumors to pursue an indolent clinical course with a significant risk of late relapse, we also strongly advocate that *all* patients with a GIST be carefully and regularly followed up for an indefinite period.

REFERENCES

1. Thomas RM, Sobin LH: Gastrointestinal cancer incidence and prognosis by histologic type, SEER population-based data 1973–1987. *Cancer* 75:154-170, 1995
2. Hirota S, Isozaki K, Moriyama Y, et al: Gain-of-function mutations of *c-kit* in human gastrointestinal stromal tumors. *Science* 279:577-580, 1998
3. Rubin BP, Fletcher JA, Fletcher CDM: Molecular insights into the histogenesis and pathogenesis of gastrointestinal stromal tumors. *Int J Surg Pathol* 8:5-10, 2000
4. Lux ML, Rubin BP, Biase TL, et al: KIT extracellular and kinase domain mutations in gastrointestinal stromal tumors. *Am J Pathol* 156:791-795, 2000
5. Kindblom L-G, Remotti HE, Aldenborg F, et al: Gastrointestinal pacemaker cell tumor (GIPACT): Gastrointestinal stromal tumors show phenotypic characteristics of the interstitial cells of Cajal. *Am J Pathol* 152:1259-1269, 1998
6. Sarlomo-Rikala M, Kovatich AJ, Barusevicius A, et al: CD117: A sensitive marker for gastrointestinal stromal tumors that is more specific than CD34. *Mod Pathol* 11:728-734, 1998
7. Berman J, O'Leary TJ: Gastrointestinal stromal tumor workshop. *HUM PATHOL* 32:578-582, 2001
8. Appelman HD: Mesenchymal tumors of the gut: Historical perspectives, new approaches, new results and does it make any difference? *Monogr Pathol* 31:220-246, 1990
9. de Saint Aubain Somerhausen N, Fletcher CDM: Gastrointestinal stromal tumours: An update. *Sarcoma* 2:133-141, 1998
10. Miettinen M, Sarlomo-Rikala M, Lasota J: Gastrointestinal stromal tumors: Recent advances in understanding of their biology. *HUM PATHOL* 30:1213-1230, 1999
11. Miettinen M, Lasota J: Gastrointestinal stromal tumors—Definition, clinical, histological, immunohistochemical and molecular genetic features and differential diagnosis. *Virchows Arch* 438:1-12, 2001
12. Mazur MT, Clark HB: Gastric stromal tumors: Reappraisal of histogenesis. *Am J Surg Pathol* 7:507-519, 1983
13. Herrera GA, Cerezo L, Jones JE, et al: Malignant small bowel neoplasm of enteric plexus derivation (plexosarcoma). Light and electron microscopic study confirming the origin of the neoplasm. *Dig Dis Sci* 29:275-284, 1984
14. Lauwers GY, Erlandson RA, Casper ES, et al: Gastrointestinal autonomic nerve tumors: A clinicopathologic, immunohistochemical and ultrastructural study of 12 cases. *Am J Surg Pathol* 17:887-897, 1993
15. Newman PL, Wadden C, Fletcher CDM: Gastrointestinal stromal tumours: Correlation of immunophenotype with clinicopathologic features. *J Pathol* 164:107-117, 1991
16. Mikhael AI, Bacchi CE, Zarbo RJ, et al: CD34 expression in stromal tumors of the gastrointestinal tract. *Appl Immunohistochem* 2:89-93, 1994
17. Miettinen M, Virolainen M, Sarlomo-Rikala M: Gastrointestinal stromal tumors: Value of CD34 antigen in their identification and separation from true leiomyomas and schwannomas. *Am J Surg Pathol* 19:207-216, 1995
18. Sircar K, Hewlett BR, Huizinga JD, et al: Interstitial cells of Cajal as precursors of gastrointestinal stromal tumors. *Am J Surg Pathol* 23:377-389, 1999
19. Lee JR, Joshi V, Griffin JW, et al: Gastrointestinal autonomic nerve tumor: Immunohistochemical and molecular identity with gastrointestinal stromal tumor. *Am J Surg Pathol* 25:979-987, 2001
20. Hornick JL, Fletcher CDM: Immunohistochemical staining for KIT (CD117) in soft tissue sarcomas is very limited in distribution. *Am J Clin Pathol* 117:188-193, 2002
21. Min K-W: Small intestinal stromal tumors with skeinoid fibers. Clinicopathological, immunohistochemical and ultrastructural investigations. *Am J Surg Pathol* 16:145-155, 1992
22. Miettinen M, Sobin LH, Sarlomo-Rikala M: Immunohistochemical spectrum of GISTs at different sites and their differential diagnosis with a reference to CD117 (KIT). *Mod Pathol* 13:1134-1142, 2000
23. Miettinen M, Monihan JM, Sarlomo-Rikala M, et al: Gastrointestinal stromal tumors/smooth muscle tumors (GISTs) primary in the omentum and mesentery: Clinicopathologic and immunohistochemical study of 26 cases. *Am J Surg Pathol* 23:1109-1118, 1999
24. Reith JD, Goldblum JR, Lytes RH, et al: Extragastric (soft tissue) stromal tumors: An analysis of 48 cases with emphasis on histologic predictors of outcome. *Mod Pathol* 13:577-585, 2000
25. Weiss SW, Goldblum JR: Extragastric stromal tumors, in Weiss SW, Goldblum JR (eds): *Enzinger and Weiss's Soft Tissue Tumors*, 4th ed. St. Louis, MO, Mosby, 2001, pp 749-768
26. Ortiz-Hidalgo C, de Leon Bojorge B, Albores-Saavedra J: Stromal tumor of the gallbladder with phenotype of interstitial cells of Cajal. A previously unrecognized neoplasm. *Am J Surg Pathol* 24:1420-1423, 2000
27. Lasota J, Carlson JA, Miettinen M: Spindle cell tumor of urinary bladder serosa with phenotypic and genotypic features of gastrointestinal stromal tumor. *Arch Pathol Lab Med* 124:894-897, 2000
28. Emory TS, Sobin LH, Lukes L, et al: Prognosis of gastrointestinal smooth muscle (stromal) tumors: Dependence on anatomic site. *Am J Surg Pathol* 23:82-87, 1999
29. Goldblum JR, Appelman HD: Stromal tumors of the duodenum: A histologic and immunohistochemical study of 20 cases. *Am J Surg Pathol* 19:71-80, 1995
30. Tworek JA, Appelman HD, Singleton TP, et al: Stromal tumors of the jejunum and ileum. *Mod Pathol* 10:200-209, 1997
31. Tworek JA, Goldblum JR, Weiss SW, et al: Stromal tumors of the abdominal colon: A clinicopathologic study of 20 cases. *Am J Surg Pathol* 23:937-945, 1999
32. Tworek JA, Goldblum JR, Weiss SW, et al: Stromal tumors of the anorectum: A clinicopathologic study of 22 cases. *Am J Surg Pathol* 23:946-954, 1999
33. Miettinen M, Sarlomo-Rikala M, Sobin LH, et al: Esophageal stromal tumors: A clinicopathologic, immunohistochemical and molecular genetic study of 17 cases and comparison with esophageal leiomyomas and leiomyosarcomas. *Am J Surg Pathol* 24:211-222, 2000
34. Appelman HD: Smooth muscle tumors of the gastrointestinal tract: What we know now that Stout didn't know. *Am J Surg Pathol* 10(Suppl 1):83-99, 1986
35. Ranchod M, Kempson RL: Smooth muscle tumors of the gastrointestinal tract and retroperitoneum: A pathologic analysis of 100 cases. *Cancer* 39:255-262, 1977
36. Evans HL: Smooth muscle tumors of the gastrointestinal tract: A study of 56 cases followed for a minimum of 10 years. *Cancer* 56:2242-2450, 1985
37. DeMatteo RP, Lewis JJ, Leung D, et al: Two hundred gastrointestinal stromal tumors: Recurrence patterns and prognostic factors for survival. *Ann Surg* 231:51-58, 2000
38. Franquemont DW: Differentiation and risk assessment of gastrointestinal stromal tumors. *Am J Clin Pathol* 103:41-47, 1995